Terrace Eye Centre

newsletter

MARCH **2018**

DR ALBERT **ARALAR**
DR PETER **BECKINGSALE**
DR MARK **DONALDSON**
DR GUY **D'MELLOW**
DR MICHAEL **HOGDEN**
DR SONIA AHN **YUEN**
DR WILLIAM **GLASSON**
DR SUNIL **WARRIER**
PROF TIM **SULLIVAN**
DR SING-PEY **CHOW**

PHONE 07 3831 0101 **www.terraceeyecentre.com.au**

Cataract Surgery at Terrace Eye Centre

Terrace Eye Centre (TEC) is well known for expert management of complex clinical and surgical subspecialty concerns as well as committed day to day care of more common ocular conditions, including routine age-related cataracts.

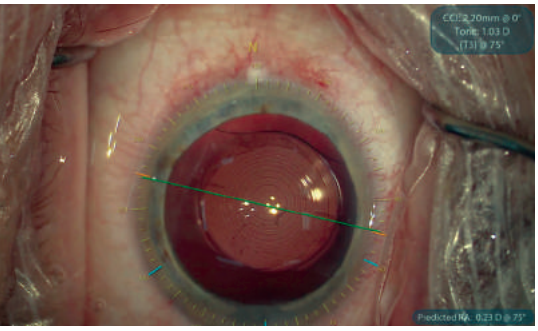

Drs Beckingsale, Glasson, Warrier, Yuen and Chow routinely deal with difficult cataracts in complicated eyes, such as in the setting of corneal transplants, retinal surgery, severe glaucoma, keratoconus, corneal dystrophy and trauma, in adults as well as in children. Management of these complex cases on routine basis helps to ensure a good outcome for more straightforward cataract surgeries.

TEC utilises the latest technology to provide a comprehensive cataract assessment to ensure the best possible surgical outcome. Optical biometry, whilst serving as the standard 10 years ago, is no longer sufficient on its own; additional assessment, including corneal topography, OCT and digital alignment systems, are important in fine-tuning the preoperative measurement to facilitate the best surgical outcome possible.

For instance, TEC has both Verion and Callisto digital alignment systems which allow a pre-operative corneal topography to be overlaid into the eyepiece of the operating microscope to provide the most accurate alignment of toric intraocular lenses for astigmatism management.

TEC cataract surgeons are also very experienced in the use of micro-trabecular glaucoma stents which may improve the intraocular pressure control in patient with inadequately controlled glaucoma or topical medication intolerance.

For patients who are looking for spectacle independence, particularly in refractive lens surgery, a wide range of intraocular lens (IOL) options are available, including diffractive trifocal IOLs, extended depth of focus IOLs as well as the mono-vision. Our extensive experience with different lenses allows a comprehensive assessment and discussion regarding the best fit between the lens and the patients, both those with healthy eyes as well as those with complex ocular issues. As well, fine tuning of visual outcome after cataract surgery, if and when needed, can be provided through laser refractive correction under the expert care of Drs. Beckingsale and Glasson, who are amongst the most experienced LASIK and PRK surgeons in Queensland.

Modern cataract surgery has become routine in most cases; however, unanticipated complications that do occur from time to time are regularly referred to TEC to be managed by our multi-specialty expert team, which includes retinal, corneal and glaucoma surgeons who are committed to timely, effective and compassionate management of these complex and urgent ocular concerns.

IN THIS ISSUE

Corneal Crosslinking now available

Corneal crosslinking (CXL) is a relatively new treatment which can effectively halt the progression of keratoconus and other corneal weakening (ectatic) disorders, such as pellucid marginal degeneration and post-LASIK ectasia.

Peschke Sapphire CXL Device

It was developed in Germany in 2003 and has been shown in many studies worldwide to be very safe and highly effective. CXL involves application of vitamin B12 (riboflavin) eye drops followed by exposure to low dose ultraviolet light, triggering a chemical reaction which results in a controlled corneal scar formation. This corneal scar remains clear and tough, resistant to further stretching and thinning and thereby halting progression in 96-98% of cases. Patients who are still in the early stages of keratoconus are often those who benefit most from CXL as the primary aim is to prevent progression. CXL is not suitable when keratoconus has already stabilised (typically after 30 years of age) or has already progressed to an advanced stage.

Our corneal subspecialists Drs Peter Beckingsale and Sing-Pey Chow provides CXL on site at TEC through the state of the art Peschke Sapphire device for patients with keratoconus and progressive corneal ectasia. Comprehensive assessment is conducted for each perspective candidate prior to CXL to ensure both the suitability as well as successful outcome for each patient.

Aussidex Trial Case Report

Recruitment for the "Aussidex" Phase IV Trial of the Dexamethasone slow release intravitreal implant has now closed. Terrace Eye Centre was the number one site in the country for this trial.

We have been very encouraged by the results of this exciting new medicine and have seen outstanding results in patients with the most severe disease.

The image at the right shows the results of one of our patients. Mr C is a 55 year old male with very poorly controlled diabetes. His vision had deteriorated over the past 12 months; he had stopped driving and gained a lot of weight. He had been very poorly compliant with his medications and frequently missed visits to the hospital and his GP. His visual acuity was down to 6/60 in each eye. Dilated retinal examination showed moderate non-proliferative diabetic retinopathy with severe clinically significant macular oedema (CSMO) in both eyes. He had mild to moderate cataracts in both eyes.

Given the severity of the CSMO in both eyes and the need for treatment in both eyes, he was a perfect candidate for Ozurdex, with the treatment was commencing in the left eye first.

On review six weeks after his first Ozurdex, the OCT shows almost complete resolution of the CSMO with improvement in visual acuity from 6/60 to 6/18.

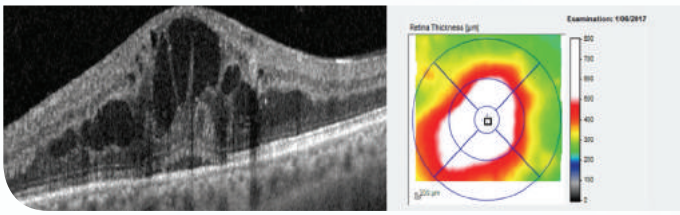

Before Ozurdex 6/60

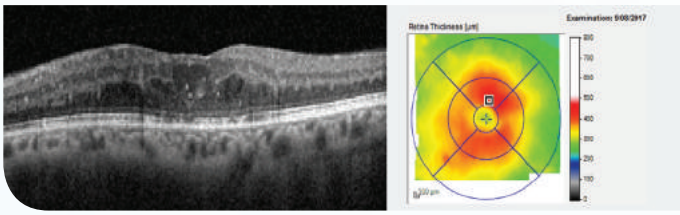

After Ozurdex 6/12

Due to the slow release nature of the Ozurdex implant, his first injection lasted for four months. The image shows his OCT scan two months after his second injection, where his visual acuity had improved enough to regain driving vision, which is a life changing improvement for this gentleman.

Oculoplastics Surgeons

Professor Tim Sullivan and Dr Sonia Ahn Yuen are long established Oculoplastics Surgeons at the Terrace Eye Centre.

Bilateral lower lid ectropion with lid eversion.

Oculoplastics subspecialty spans a wide spectrum of eye conditions involving the eyelid, lacrimal and orbital diseases both for adult and paediatric patients. Specific disorders include periocular and orbital carcinomas (e.g. basal cell carcinomas and squamous cell carcinomas), vascular and other lesions, tear duct abnormality (e.g. obstruction and malformation) as well as eyelid malposition (e.g. ptosis, ectropion, retraction and entropion), both in congenital and acquired settings. Dr Sullivan and Dr Yuen are both consultant oculoplastics surgeons at the Royal Brisbane and Women's Hospital and Lady Cilento Children's Hospital, where they are committed to serving the needs of the community as well as teaching the next generation of doctors.

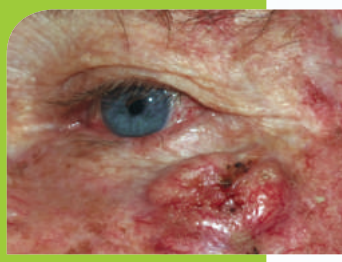

Periocular squamous cell carcinoma

Paediatric Ophthalmology at Terrace Eye Centre

Dr. Sonia Ahn Yuen subspecializes in Paediatric Ophthalmology (in addition to Oculoplastics and General Ophthalmology).

Paediatric ophthalmology spans a wide spectrum of eye disorders in children, including strabismus, amblyopia and congenital cataract. Strabismus includes esotropia, exotropia, hypertropia, hypotropia as well as other less common ocular misalignment, such as dissociated vertical deviation.

A child with esotropia.

Unilateral leukocoria with left congenital cataract.

Bilateral congenital nasolacrimal outflow obstruction.

Amblyopia management is a part of rigorous visual rehabilitation regimen for children, typically involving patching, which requires close monitoring and management. Cataract presenting in children differs significantly from that in adults and needs to be managed promptly and appropriately regarding both potential surgical intervention as well as long term visual development.

More urgent assessment is needed for certain potentially vision and life threatening ocular presentation, such as leukocoria and pupillary abnormality (e.g., anisocoria, fixed pupil and afferent pupillary defect).

Dr Yuen has been a long established consultant at the Terrace Eye Centre as well as within the public system, initially at the Royal Children's Hospital and currently at the Lady Cilento Children's Hospital.

Oncogenomics collaborative research synopsis

Research into the genetics of uveal melanoma (UM) conducted through a collaboration between Prof. Nicholas Hayward's Oncogenomics group at the QIMR Berghofer Medical Research Institute and the Terrace Eye Centre Queensland Ocular Oncology Service clinicians, Drs William Glasson and Sunil Warrier, has continued in 2017 on multiple fronts.

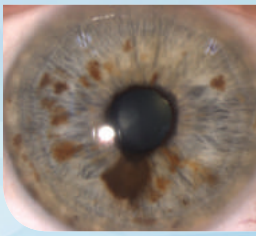

Broadly, the work has focused on two main areas: susceptibility to UM and molecular changes occurring during the development of UM.

To characterize the underlying predisposition to UM, the team has conducted whole-genome sequencing of individuals with UM and some of their family members to specifically identify rare DNA variants present only in UM patients but not in healthy controls.

This has confirmed that the main UM susceptibility gene is *BAP1*; however, the mutations in this gene only account for the risk of developing UM in about 2–4% of all cases.

No other major UM predisposition genes have been identified at this stage, but numerous candidate genes are under further investigation.

Molecular analyses conducted by our team and others have revealed that UM tumours have a very low number of acquired mutations, which are not caused by ultra-violet radiation (UVR), the main cause of cutaneous melanomas. These studies have shown that UM carries mutations in a small number of critical driver genes, which appear to be essential for the development of these tumours. However, the precise mechanism by which these mutations give rise to UM remains unknown.

A major aim of our research is to characterize the cellular signalling pathways that are corrupted by these mutations, as this may provide a clue for the treatment of this devastating disease.

OCT Angiography

Terrace Eye Centre was one of the first practices in Queensland to obtain the Heidelberg Spectralis OCT Angiography system.

This provides incredible vascular detail in a safe, non-invasive manner, without the need for dye injection. These scans are much faster, more comfortable and cost-effective for the patient than standard dye injection angiography. We are proud to announce the arrival of the latest software which makes scans even faster and removes projection artefacts. It also offers improved segmentation of Bruch's membrane for detection of choroidal neovascularisation. This exciting new technology has almost completely replaced dye injection angiograms for new wet AMD patients and allows us to continue to offer same day diagnosis and treatment for anyone referred in with a new potential diagnosis of wet AMD. A diagnosis of wet macular degeneration is extremely upsetting for most patients and TEC will endeavor to offer timely appointments for these patients to minimise progressive visual loss and anxiety.

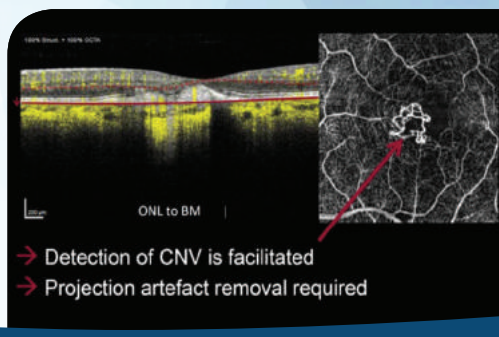

Glaucoma: The importance of accurate diagnosis by Dr Guy D'Mellow

While glaucoma is defined as a disease of the optic nerve with typical structural changes in the nerve, along with corresponding characteristic changes in the visual field, it is not one single disease.

There are many different types of glaucoma, some common, some rare and the prognosis and treatment sometimes differ. This is similar to other diseases such as arthritis where there are varying types such as osteoarthritis, rheumatoid arthritis, psoriatic arthritis etc. These have variable degrees of severity and require different approaches to treatment.

In glaucoma, one feature that contributes to the diagnosis is the status of the angle between the iris and the back surface of the cornea which forms the front of the eye. This area contains a specialised tissue called the trabecular meshwork across which passes the aqueous humor. If this fluid is unable to adequately escape from the eye, the intraocular pressure increases, potentially damaging the optic nerve. To examine this area of the eye, a mirrored lens is placed on the surface of the eye. This enables the ophthalmologist to see this tissue in detail.

The angle may be structurally open or closed. Primary open angle glaucoma is the most common form of glaucoma in Australia occurring in around 3% of the adult population. Other secondary types of open angle glaucoma include Pigmentary glaucoma, Pseudoexfoliation syndrome, and traumatic glaucoma.

In Pigmentary glaucoma, fine pigment is shed into the aqueous fluid from the iris rubbing against the front surface of the lens. In simple terms, this travels with the aqueous like silt in a stream and blocks the trabecular meshwork. This can be seen as a dense band when the area is examined.

Pseudoexfoliation syndrome results in the deposition of a fibrillary protein on the anterior surface of the lens and elsewhere in the front of the eye. As with pigmentary glaucoma, this material and associated shed pigment may block the trabecular meshwork.

If an eye suffers sufficient blunt trauma, hydraulic damage may occur in the anterior chamber angle. This can result in elevated pressure at the time or many years after the injury.

The angle may also be structurally closed in glaucoma. This may be either a primary process or secondary to other eye diseases such as chronic intraocular inflammation or retinal ischaemia. The latter produces the aggressive process of neovascular glaucoma with new blood vessels growing across the trabecular meshwork, often producing high pressures in very painful eye.

These different subtypes of glaucoma can have quite different prognoses. Pseudoexfoliation for example, tends to present with higher pressures and be more difficult to manage than primary open angle glaucoma. Neovascular glaucoma needs urgent intervention and is often hard to control with eyedrops alone.

So the question is not just "does your patient have glaucoma?" but if you do, "what type of glaucoma is it?" All glaucomas are not the same and require individualised approaches to treatment. This most commonly involves the use of eyedrops but at times Selective Laser Trabeculoplasty, MIGs procedures, or glaucoma drainage procedures are necessary.

With their considerable training and expertise, our doctors at Terrace Eye Centre can accurately diagnose whether they have glaucoma and importantly, what type of glaucoma in order to ensure that you receive the most appropriate treatment.

New AMD treatments

Dr Donaldson and Dr Aralar were in the audience at the recent American Academy of Ophthalmology meeting where the long awaited results of the HAWK and HARRIER trials were announced. These two double masked phase III trials of 1800 patients evaluated a new and exciting molecule to treat wet AMD: Brolucizumab, previously known as RTH258 is a single chain antibody fragment that inhibits all isoforms of VEGF-A and is much smaller than Ranibizumab (Lucentis) and aflibercept (Eylea). The small size of Brolucizumab allows delivery of a much higher concentration than current agents and these trial results support a longer duration of action, potentially up to 12 weeks. In addition, the smaller size allows much more rapid systemic clearance and even greater systemic safety despite a higher dose. We will be following these exciting developments closely and eagerly awaiting news of FDA clearance. While we are able to extend the treatment intervals for many patients out to 8–10 weeks using the treat and extend strategy with Lucentis and Eylea, for those patients with very active disease requiring four weekly injections, the potential for a 12 week duration of action is very exciting.

Another nail in the coffin for Fovista

(pegpleranib)

Also reviewed at the recent American Academy of Ophthalmology meeting in New Orleans was the failure of the third Phase 3 trial for Fovista in Wet Age Related Macular Degeneration. An earlier Phase 2 study revealed a significant improvment in vision when combination of Fovista and Lucentis was administered vs Lucentis monotherapy. This held some promise as a new way of treating wet AMD via inhibition of Platelet Derived Growth Factor. Unfortunately two, larger Phase 3 trials failed to show a clear benefit of combined Fovista/Lucentis over Lucentis monotherapy. A subsequent trial of combined Fovista/Eylea therapy vs Eylea montherapy with approximately 300 enrolled patients also found no advantage of using combined thereapy.

This was a disappointing finding for Fovista. However, other novel drugs, including brolucizumab and abicipar, continue to be actively trialled.